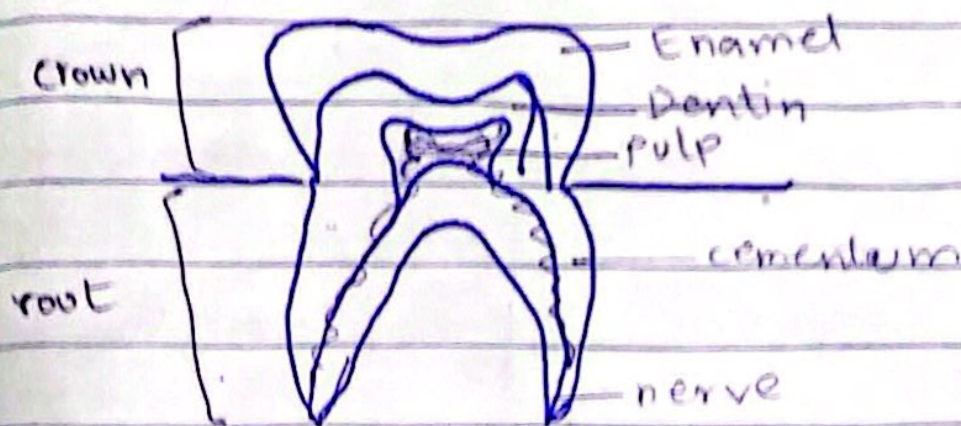


(d)

## Anatomy of Human tooth

Human tooth is a complex structure and is divided into; crown, enamel, dentin, pulp and root, etc.



### → Crown:

It is the visible part of the tooth and appears white.

### → Enamel:

The outermost layer of the tooth, specially visible on the crown of the tooth.

### → Dentin:

It is a layer of mineralized tissue that runs from crown to root and protects the tooth.